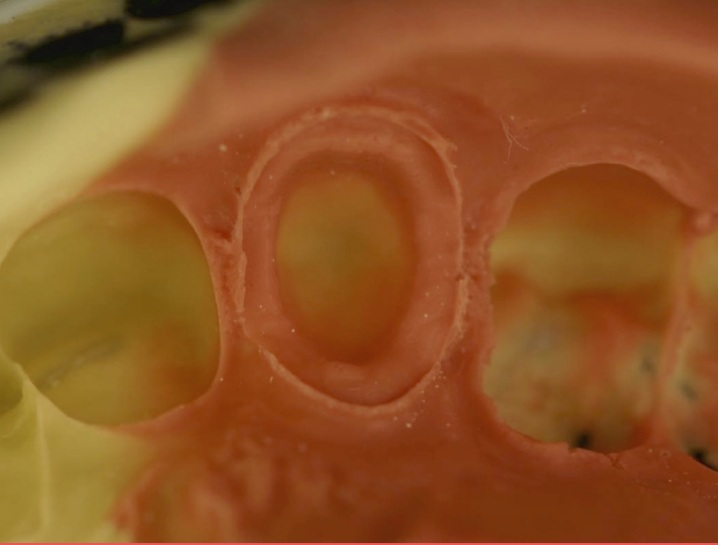





FIXED IMPRESSIONS WORK MAT

Most Common Problems with Fixed Impressions



AN EXCELLENT IMPRESSION

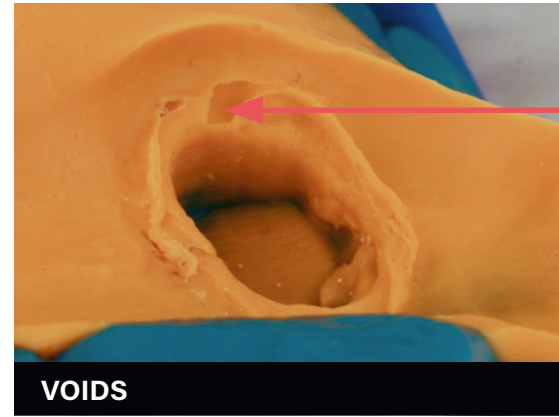
- No tearing of the wash from the putty around the preparation
- Detailed and complete margins
- No tooth contact with tray; impression centered on tray
- Tray adhesive applied properly
- Properly mixed material; no streaking
- Strong bond between tray and wash materials; no signs of debonding or ledges
- No voids; full, smooth wash material coverage



INADEQUATE MARGINS

Probable Causes:

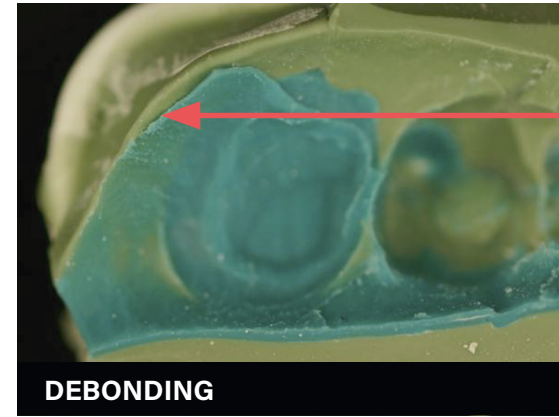
- Incomplete sulcular expansion around the preparation
- Improper moisture control around the preparation
- Exceeding the material's working time
- Tray movement after seating



VOIDS

Probable Causes:

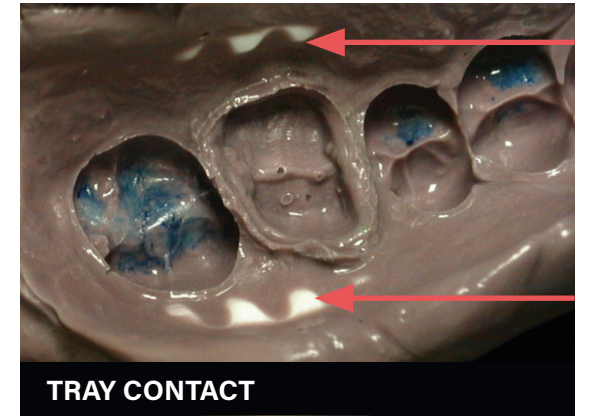
- Improper syringe technique
- Sulcular fluid/bloods/contaminants
- Incomplete sulcular expansion around the preparation
- Tray incorrectly seated
- Insufficient preparation covered by the impression material



DEBONDING

Probable Causes:


- Exceeding the material's working time
- Contamination of tray material
- Impression material stored at a temperature above manufacturer's recommendation



TRAY CONTACT

Probable Causes:

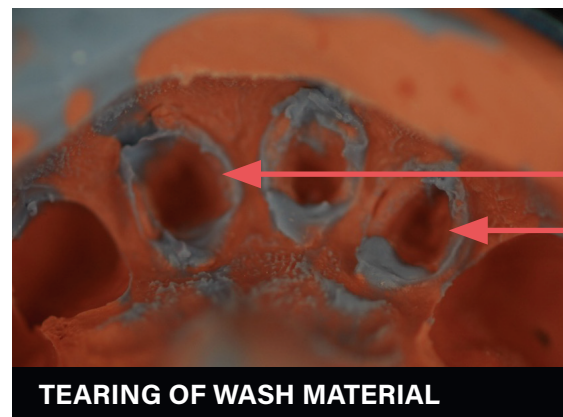
- Incorrect tray size used
- Tray not oriented correctly
- Insufficient impression material used



INADEQUATE IMPRESSION RETENTION

Probable Causes:

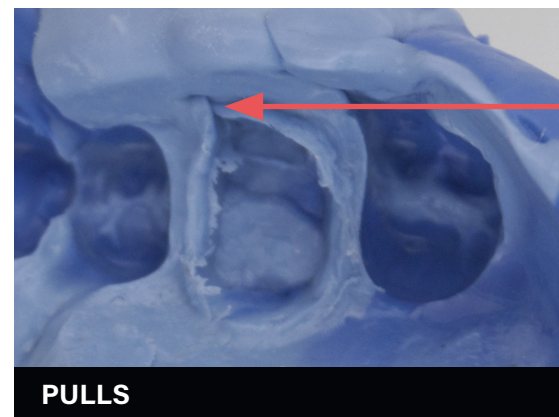
- Insufficient impression material used
- No tray adhesive used
- Inadequate tray adhesive drying time
- Outdated impression material used



TEARING OF WASH MATERIAL

Probable Causes:

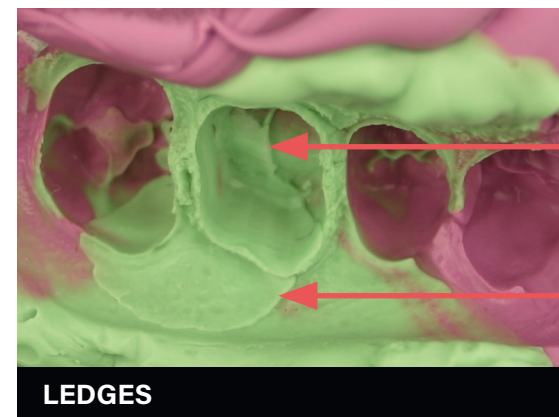
- Insufficient retraction around the preparation
- Impression removed before material has set
- Improper moisture control around the preparation
- Outdated impression material us



PULLS

Probable Causes:

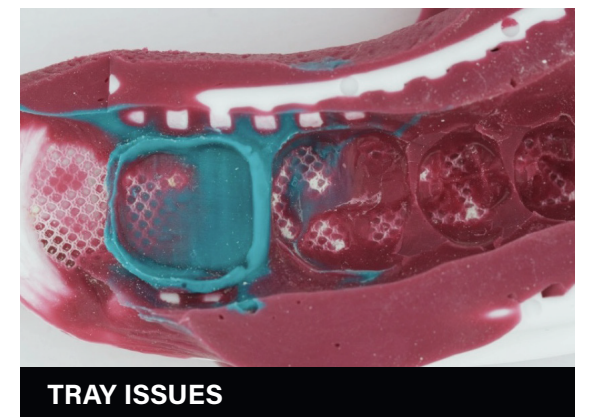- Exceeding the material's working time
- Tray movement after seating the impression
- Insufficient impression material used
- Rapid seating of the impression tray



LEDGES

Probable Causes:

- Preparation of most posterior tooth is contraindicated with dual-arch trays
- Buccal, lingual and posterior tray contact
- Lack of occlusal clearance
- Extreme mesh exposure



TRAY ISSUES

Probable Causes:

- Incomplete sulcular expansion around the preparation
- Improper moisture control around the preparation
- Exceeding the material's working time
- Tray movement after seating